



Aggressive late Sezary syndrome with pregnancy: A case presented with generalized erythroderma and dyspnea

Ahmed Samy El-Agwany¹

¹Department of Obstetrics and Gynecology, Faculty of Medicine, Alexandria University, Egypt

ABSTRACT

Introduction:

Non-Hodgkin lymphoma with pregnancy produces management dilemma regarding obstetrical aspect.

Methods and results :

This case report delineates the management of a patient diagnosed as Non-Hodgkin's lymphoma 2 weeks after delivery with ultimate demise of the patient from progressive disease 3 months after delivery.

Conclusion:

The incidence of NHL is increasing and is associated with an increased risk of maternal and neonatal morbidity and mortality, and as such, women with NHL may best be managed in specialized centers. Skin lesions should be investigated appropriately to exclude cutaneous lymphoma.

Keywords: Lymphoma, Pregnancy, Mortality, Skin Lesion.

SOMMARIO

Introduzione:

Il Linfoma non-Hodgkin, durante la gravidanza, crea un dilemma nella gestione dell'aspetto ostetrico.

Metodi e risultati:

Questo caso mostra la gestione di una paziente diagnosticata con linfoma Non-Hodgkin, 2 settimane di dopo il parto con decesso del paziente per la progressione della malattia 3 mesi dopo il parto.

Conclusione:

L'incidenza di NHL è in aumento ed è associata con un aumento del rischio di morbidità materna e neonatale e di mortalità, e quindi, le donne con NHL possono essere meglio gestite in centri specializzati. Le lesioni cutanee dovrebbero essere studiate in modo appropriato per escludere un linfoma cutaneo.

INTRODUCTION

The incidence of Non-Hodgkin lymphoma during pregnancy is rare, with fewer than one hundred cases reported⁽¹⁾. Most Non-Hodgkin lymphomas that occur during pregnancy are aggressive and delay of therapy until after delivery appears to have poor outcomes according to anecdotal case series. Consequently, some investigators favor immediate therapy, even during pregnancy. Termination of pregnancy in the first trimester may be an option to allow chemotherapy with or without radiation therapy for women with aggressive NHL. During the second and third trimester of pregnancy early

delivery when feasible may minimize or avoid exposure of the fetus to chemotherapy or radiation therapy. When possible, treatment should be postponed until after an early delivery. Women with indolent (slow-growing) Non-Hodgkin lymphoma can usually delay treatment during pregnancy with watchful waiting unless there are clear indications for treatment, such as: local symptoms due to progressive or bulky nodal disease, compromise of normal organ function presence of symptomatic extranodal disease, such as effusions, cytopenias due to extensive bone marrow infiltration, autoimmune hemolytic anemia or thrombocytopenia, or hypersplenism⁽²⁾.

Hodgkin disease is the most prevalent lymphoma type seen in pregnancy due to age distribution of patients⁽³⁾. But it is very rare to see NHL in pregnancy. Only 75 cases were reported

Correspondence to: Ahmedsamyagwany@gmail.com

ahmed.elagwany@alexmed.edu.eg

Copyright 2015, Partner-Graf srl, Prato

DOI: 10.14660/2385-0868-50

between 1937 and 1985⁽⁴⁾. Prognosis is bad in a high level NHL and average life period is 1.5 years; but in a low level one, prognosis is better and average life period is 7.5 years⁽⁵⁾. Lymphomas during delivery are high level. Non-Hodgkin's lymphoma (NHL) is considered the fourth most common cancer in pregnancy⁽⁶⁾. In 1985, NHL in pregnancy was estimated to occur in 0.8 cases per 100 000 women, whereas more recent rates suggest 1-5 per 100 000 pregnancies^(7, 8). The low incidence of pregnancy associated non-Hodgkin's lymphoma (PANHL) has precluded large clinical trials, and data is restricted to retrospective series and case reports⁽⁹⁾. Increased maternal mortality rates may also be due to the reported advanced-stage disease at diagnosis in the majority of patients with PANHL^(10, 11).

CASE REPORT

A 32 year old woman, G2P1, previous 1 cesarean section was presented to shatby maternity university hospital on 1/1/2016 with red itchy scaly plaques and papular skin lesions in a dark skin colored patient at 39 weeks of gestation for delivery for elective cesarean section. No medical disease was detected. The lesions were not properly investigated by the junior staff. They were falsely diagnosed as pruritic papular and plaque of pregnancy. Cesarean section was done and patient was discharged home after 48 hrs. She was readmitted one week after discharge with infected gapped skin wound with the generalized scaly skin lesions with darkening of skin color. Dermatology consultation was done where skin biopsy and CT were recommended revealed cutaneous T-cell lymphoma as mycosis fungoides. CT revealed bilateral enlarged intraparotid lymph nodes, largest in the right about 2 cm, bilateral jugular LN, largest was 1 cm, bilateral enlarged axillary LN, largest was 3.5 cm, bilateral enlarged inguinal LN, largest was 3.5 cm, enlarged submental LN, largest was 1 cm and no mediastinal or paraortic enlarged LN with diffuse subcutaneous oedema. Single cycle chemotherapy was started but dyspnea occurred with desaturation at room temperature, pain in the right side of the chest. She was a non-smoker and had no prior history of tuberculosis or bronchial asthma. Chest Xray (**Figure 1**) revealed right pleural effusion. Ultrasonography guided Fine Needle Aspiration Cytology (FNAC) revealed Non-Hodgkin Lymphoma. Bone marrow was not done as the stage of NHL was advanced at the time of presentation. Examination revealed

full blown picture of sezary syndrome inform of lid ectropion,generalized erythroderma with scaling,brittle nails and palmar, plantar hyperkeratosis (**Figure 2-4**). Hb was 7.8 gm/dl, WBC 1000/cmm,PLT 110000/cmm, SGOT 945, SGPT 1026 IU/L, creatinine 3.45 mg%, INR was 3, albumin 1.4 g/% and high blood glucose level. Mechanical ventilation was done but the patient arrested and died about 2 weeks about 3 months from delivery from cardiorespiratory failure due to progressive disease.

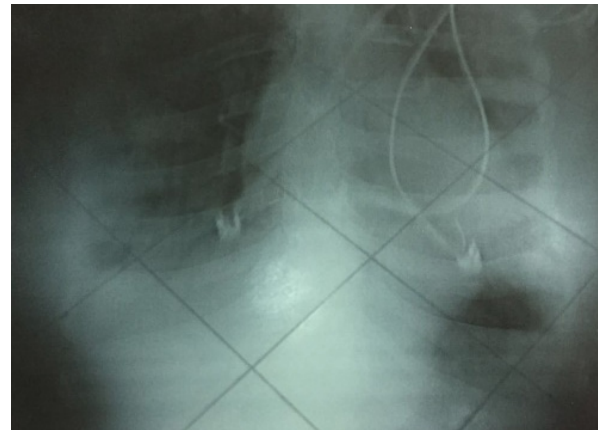


Figure 1. X-ray with right pleural effusion.

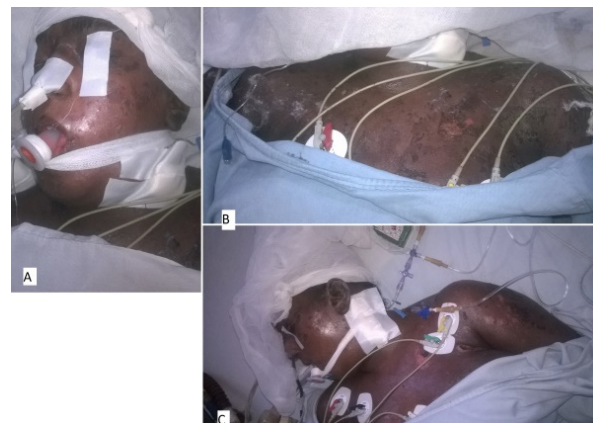

Figure 2. Intubated female for respiratory distress with skin lesions and exfoliation over face, chest and upper limb..

DISCUSSION

The prognosis, survival and response of NHL to therapy are related to the histological variant. According to the most accepted classification of Non-Hodgkin's Lymphoma proposed by Rappaport, the diffuse types have a poorer prognosis than nodular ones⁽¹²⁾. Aggressive lymphomas also called intermediate-grade and high-grade lymphomas grow and spread quickly and are usually associated with severe symptoms.

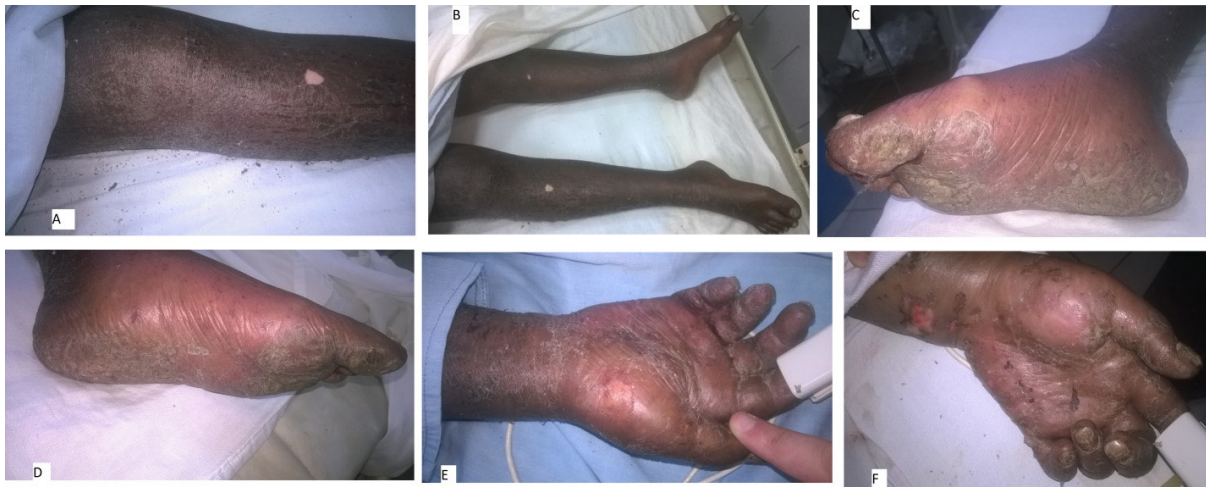

Figure 3. Generalized erythroderma with oedema and scaling, palmar and plantar hyperkeratosis of all limbs.

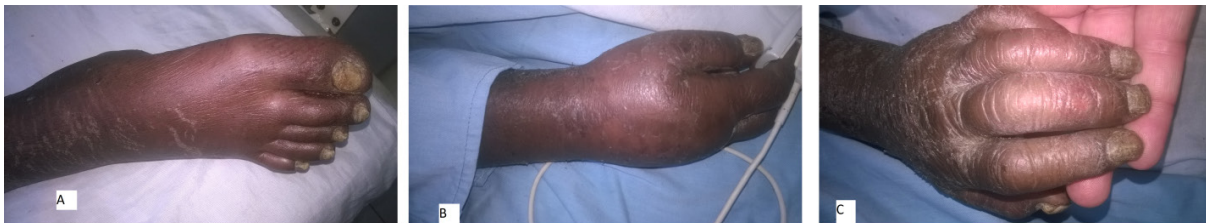

Figure 4. Brittle nails characteristic of sezary syndrome

Aggressive lymphomas are seen more frequently in patients who are HIV-positive, in patients who are on immunosuppressant therapy after organ transplantation or those who have been treated previously for Hodgkin lymphoma or in the presence of inherited immune disorders⁽¹⁴⁾. In our case no tests were done to find out the possible cause of development of Non-Hodgkin's Lymphoma, but pregnancy itself is a state of immunosuppression.

According to the Ann Arbor Classification of Non-Hodgkin Lymphoma, NHL Stage IV indicates extensive (diffuse) involvement in one organ or site, with/without NHL in distant lymph nodes as our case.

The treatment approach should be individualized according to the period of gestation, stage and localization of the disease, the presence or absence of B symptoms (fever, night sweats, and weight loss of more than 10% of the original weight six months prior to first attendance) and the progression of symptoms and signs⁽¹⁵⁾. Almost all NHL in pregnancy is high grade and most rapid tumour growth is thought to occur in early pregnancy and puerperium especially during lactation as our case. Tumour masses of non-Hodgkin's lymphoma greater than 10 cm in size or mediastinal mass occupying more than half

of the transverse thoracic diameter and raised serum LDH represent poor prognostic signs. Although both radiotherapy and chemotherapy are potentially teratogenic, they can be used safely in some circumstances during pregnancy. A variety of protocols of combination chemotherapy (CT) has been used for the treatment of NHL in pregnancy in the reported cases with variant outcomes. These are CHOP, (cyclophosphamide, vincristin, adriamycin, prednisolone), VACOP-B, CHOP with rituximab and last of all, autologous stem cell transplantation with high-dose CT and ESHAP protocol (Etoposide VP16, Cisplatin, methylprednisolone and ephosphomide)⁽¹²⁻¹⁶⁾.

Radiation with proper shielding can also be given above the diaphragm during the first trimester. Later on it can be used only in areas away from the foetus⁽³⁾. Chemotherapy alone cures 30% to 40% of patients with advanced disease of Stage III or Stage IV. Two strategies for treating localized intermediate and high grade Non-Hodgkin's Lymphoma has emerged without any convincing evidence in favor of either strategy over the recent decades: Chemotherapy alone with CHOP for 6-8 cycles, or a short course of Chemotherapy (usually 3 cycles of CHOP) followed by involved-field Radiotherapy. The presumed advantages of chemotherapy alone are avoidance

of long-term complications of radiotherapy and the higher total doses of systemic therapy which increases the potential for eliminating microscopic sites of disease. The possible benefits of short course Chemotherapy followed by Radiotherapy are the reduction in the risk of cardiac toxicity due to the lower total dose of Doxorubicin, the use of two treatments and the advantage of radiation directly to sites of detectable disease⁽²⁰⁾.

Cutaneous lymphomas are a distinct subset of non-Hodgkin's lymphoma (NHL), and that they can be divided into cutaneous B-cell lymphomas and cutaneous T-cell lymphomas. Unlike most other types of lymphoma, which develop in lymph nodes, people with cutaneous lymphoma have a cancer of lymphocytes that develops primarily in the skin. CTCL is the acronym for cutaneous T-cell lymphoma, a general term for several types of lymphomas of the skin that derive from T-cells, including mycosis fungoides, Sézary syndrome, primary cutaneous anaplastic large cell lymphoma, lymphomatoid papulosis, granulomatous slack skin disease, pagetoid reticulosis, and subcutaneous panniculitis-like T-cell lymphoma. Most CTCLs typically fall into the category of indolent (i.e. chronic) lymphomas-treatable, but not curable and usually not life-threatening. In CTCL, malignant T-cells travel to the upper layers of the skin, causing a rash, which leads to diagnosis. CTCL is sometimes wrongly referred to as a skin cancer because it affects the skin, but this is not a precise use of the term "skin cancer". Skin cancer is the designation for cancers that develop from other, non-lymphoid cells of the skin, including epidermal cells (which lead to squamous cell carcinoma) and melanocytes or pigment cells and (which lead to melanoma). More common among men than women, CTCL occurs more in patients older than 50 years of age than in younger people.

It is important to know, too, that CTCL is not contagious. It is not an infection and cannot be passed from person to person. There is no known cure for CTCL, though some patients enter long-term remission with treatment and live symptom-free for many, many years. The most recent research indicates that patients diagnosed with the early stages of the most common type of CTCL - mycosis fungoides (which makes up about 70% of CTCL) - have a normal life expectancy. The two most common types of CTCL are mycosis fungoides (MF) and Sézary syndrome (SS). Together, they make up about three quarters of all CTCL. Mycosis fungoides is the most common form of CTCL. Because of that, the terms

MF and CTCL are often used interchangeably, and sometimes imprecisely. MF is an indolent type of CTCL, follows a slow, chronic course and very often does not spread beyond the skin. Over time, in about 10% of cases, it can progress to lymph nodes and internal organs.

Symptoms of MF can include flat, red, scaly patches, thick raised lesions, and sometimes large nodules called tumors. The disease can progress over many years, often decades. MF patches and plaques are often mistaken for eczema, psoriasis or "non-specific" dermatitis until an exact diagnosis is made. A common characteristic is itching. MF is very difficult to diagnose in early stages as symptoms and skin biopsy findings are similar to other skin conditions, leading to frequent misdiagnosis. Patients may go on for years before a definitive diagnosis is established. Both the clinical findings (based on both history and examination) and the skin biopsy findings are essential for diagnosis. Sézary syndrome is a less common but more aggressive type of CTCL that is related to MF but presents with very severe itching, total body redness (erythroderma), intense scaling of the skin and frequent hair loss. Lymph nodes are usually enlarged, and the malignant T-cells found in the skin are also seen circulating in the bloodstream. SS is the only type of CTCL that always affects the skin and the blood.

The skin may be red from head to toe. Tumor cells are found in the blood, and lymph nodes are larger than usual. The skin may be hot, sore, extremely itchy, occasionally flaking and burning. Oozing of clear fluid from the skin is common. Because much heat is lost through the skin, people often feel cold. Symptoms may be accompanied by changes in nails, hair or eyelids. Approximately 15% of patients with CTCL have SS. This disease usually occurs in adults older than 50 and is found more in men than women. In general, B-cell non-Hodgkin's lymphomas are much more common than T-cell non-Hodgkin's lymphomas (85% versus 15%). However, in the skin, the opposite is true: CTCL makes up about 75-80% of all cutaneous lymphomas, whereas CBCL makes up about 20-25%. CBCLs are B-cell non-Hodgkin's lymphomas which originate in skin-based B-cells. The fact that most skin-resident lymphocytes are T-cells, rather than B-cells, may explain the difference. Following are stages for mycosis fungoides and Sézary syndrome: Stage IA: Less than 10% of the skin is covered in red patches or plaques. Stage IB: 10% or more of the skin is covered in patches or plaques. Stage IIA: Any amount of the skin surface is covered with

patches or plaques and lymph nodes are enlarged and inflamed, but the cancer has not spread to the nodes. Stage IIB: One or more tumors are found on the skin, lymph nodes may be enlarged, but cancer has not spread to the nodes. Stage III: Nearly all of the skin is reddened and may have patches, plaques or tumors; lymph nodes may be enlarged, but cancer has not spread to them. Stage IVA: Most of the skin is reddened and malignant cells are found in the blood; cancer has spread to the lymph nodes. Stage IVB: Most of the skin is red, any amount of skin is covered in patches, plaques or tumors, cancer has spread to other organs. Tumors are raised "bumps" or "nodules" which may or may not ulcerate. To be called a tumor, generally a nodule has to be at least 1 cm in size, or greater.

A common symptom is itching.

The most common form of cutaneous lymphoma, mycosis fungoides, often presents with an area of red, slightly scaly skin, usually in sun-protected parts of the body, with variable size and shape. Common locations for these symptoms are the buttocks, trunk, upper thighs - all areas that are typically shielded from sun exposure. Patients with cutaneous lymphoma find their outbreaks in sun-protected areas of the skin because the natural UV component of sunlight may have a protective effect against mycosis fungoides. The exact reason, however, is not known. Sézary syndrome (SS) is one type that can present in generalized redness affecting 80% or more of the skin's surface. Patients with SS tend to experience very intense itching, perhaps the most intense and relentless itching that has ever been described. They often lose large amounts of skin during the night and may find their bed sheets covered with skin flakes in the morning. This variation presents more dramatically than other types of the disease, making it easier to diagnose because the presentation is more unusual. Sézary syndrome patients will likely also feel tired, have enlarged lymph nodes, may run a fever and just generally feel sick. Common Signs & Symptoms of Sézary Syndrome: Diffuse scaling skin (erythroderma), Thickening of palms and soles (hyperkeratosis), Hair thinning, Eyelid margin thickening (ectropion), Itching and Enlarged lymph nodes. The process for diagnosis is similar for all types and may include a physical exam and history; blood tests to identify antigens, or markers, on the surface of cells in the blood; and a skin biopsy (removal of a small piece of tissue) for examination under the microscope by a pathologist (a doctor who studies tissue and

cells to identify disease). Bone marrow biopsy may occasionally be necessary to verify complete staging of the disease. This is more likely to be needed with cutaneous B-cell lymphomas than cutaneous T-cell lymphomas.

To conduct an effective, informative biopsy, patients need to be off topical steroids and ultraviolet light treatment regimens for at least a week or two. While these treatments may provide temporary symptom relief, they can also mask potential symptoms of skin lymphomas and thus delay a patient's definitive diagnosis. Cutaneous T-cell lymphoma is a complex disorder which often takes a significant amount of time to diagnose. Various studies indicate that the average time from first appearance of symptoms to confirmed diagnosis of the disease ranges from two to seven years. This delay can lead to frustration for both the patient and healthcare providers. The most useful test is a skin biopsy because lesions that appear very similar on the skin may look quite different under the microscope. Many patients require multiple biopsies before a satisfying and complete diagnosis is made. The need for multiple, sequential biopsies can be exasperating and difficult for patients to understand. Mycosis fungoides is difficult to diagnose in early stages as the symptoms and skin biopsy findings are similar to those of other conditions.

The best way to manage a disease like cutaneous lymphoma is by assembling the right team of physicians and support individuals to guide your treatment course as dermatologist, oncologist, radiation oncologist. Early stages have typically been treated with skin-directed therapy by dermatologists, with little oncology input, and advanced stages have typically been treated with systemic therapy by oncologists, with little dermatology input. The only better alternative to this scenario is the ideal situation of a multidisciplinary clinic, where the entire team of doctors is wholly focused and dedicated to the care of patients with cutaneous lymphoma. Multidisciplinary clinics, by definition, have an oncologist and a dermatologist on site, both in a leading role, in addition to a large number of additional supporting staff. Such clinics, unfortunately, are available only in a small number of selected cancer centers. Treatment choices for cutaneous lymphoma are directed at either the skin (topical) or the entire body (systemic). Medications you put on the skin including topical corticosteroids, chemotherapies, and retinoids (made from Vitamin A).

- Light therapy (phototherapy) that exposes affected areas of the skin to special ultraviolet (UV) rays.

- Radiation therapy that uses high-dose X-rays .Biologic therapies (or immunotherapies) use the body's own immune system to fight cutaneous lymphoma.

- Retinoids are Vitamin-A related compounds that are active in treating cutaneous lymphoma.

- Extracorporeal photopheresis (ECP) involves taking blood from a vein and passing it through a machine, where it is treated with a drug that makes white blood cells (particularly T-lymphocytes) more sensitive to UV light. The blood is then exposed to UV light and returned to the body.

- Chemotherapy uses a single anticancer drug or a combination of drugs.

Chemotherapy uses chemicals that interfere with cell division, Bone marrow or stem cell transplantation is considered in cases for patients with advanced disease In general, early-stage patients (IA, IB, IIA) should consider topically-applied medications or ultraviolet light therapy over pills and IV medications because they are usually very effective, have fewer side effects, and the prognosis is usually very good. Chemotherapy administered as single agent or in combination may be used to treat the manifestations of advanced cutaneous lymphoma. Combination or multi-agent chemotherapy is usually reserved for advanced stages of disease. Methotrexate (Matrex[®]) is an anti-metabolite agent used for a host of immune-based diseases. It interferes with folic acid metabolism in cancer cells. In cutaneous lymphoma, this is administered in oral form by pill weekly. Pralatrexate (Foloty[®]) is used in the treatment of transformed mycosis fungoides and other aggressive non-Hodgkin's lymphomas such as peripheral T-cell lymphoma. It is a folate metabolic inhibitor which targets the same pathway as methotrexate. Patients receiving pralatrexate therapy take a daily dose of folic

acid and receive Vitamin B12 injections every 8 to 12 weeks. It is delivered intravenously every 3 weeks, followed by a rest week. Alemtuzumab (Campath[®]) is a monoclonal antibody directed against the CD52 antigen (surface marker) found on both B-lymphocytes and T-lymphocytes. The use of chemotherapy drug combinations in cutaneous lymphoma should be discouraged because they have never been proven to be more effective than sequential single agents, and they are always much more toxic. Combinations such as CHOP (cyclophosphamide, doxorubicin, vincristine, and prednisone), ESAHP (etoposide, solumedrol, high-dose ara-C, and cisplatin), and GND (gemcitabine, navelbine, and doxil) may be used when no other therapy is available, or in rare circumstances as a way to produce brief responses in preparation for a bone marrow transplant.

CONCLUSION

Lymphoma is a rare disease in pregnancy. The diagnosis of NHL in pregnancy may be delayed because of reluctance to subject the patient to investigation of skin lesions, X-rays and surgical procedures for the non-specific symptoms also may be mistaken for normal dermatoses of pregnancy. Therefore this diagnostic delay should be avoided by all means maintaining a liaison between haematologist, oncologist and obstetrician. Doctors should be a ware of the normal skin lesions differentiating it form abnormal ones.

Darkening of skin color especially hidden areas from sun, generalized skin lesion, scaling, redness and hyperkeratosis are not normal in pregnancy. Cutaneous cell lymphoma should be excluded in any skin lesion during pregnancy by dermatological consultation.

REFERENCES

- 1) Habib F.A. **Pregnancy in a patient with non-Hodgkin lymphomas:** Qatar Medical journal 2002; 11(1).
- 2) **Non-Hodgkin's Lymphoma During Pregnancy, General Information About Non-Hodgkin Lymphoma** During Pregnancy. <http://cancer.gov>
- 3) Macfarlane GJ, Evstifeeva T, Boyle P. **International patterns in the occurrence of Hodgkin's disease in children and young adult males.** Int J Cancer

- 1995;61:165-9.
- 4) Beksaç MS. **Maternal Fetal Tıp ve Perinatoloji.** Ankara: Nobel, 2001;733-4.
- 5) Haznedar R. **Hematolojik Hastalıklar.** Ankara: Günefl Kitabevi, 1996;1:10:1298-1312.
- 6) Horowitz NA, Benyamini N, Wohlfart K, Brenner B, Avivi I. **Reproductive organ involvement in non-Hodgkin lymphoma during pregnancy:A systematic review.** Lancet Oncol 2013; 14: 275-282.

- 7) 19. McLaren J, Taylor DJ, Bell SC. **Increased incidence of apoptosis in non-labour-affected cytotrophoblast cells in term fetal membranes overlying the cervix.** Hum Reprod 1999; 14: 2895- 2900.
- 8) Jesus Ortega. **Multiple agent chemotherapy including bleomycin of non-hodgkin's lymphoma during pregnancy;** Cancer cytopathology CA: A cancer journal for clinician. 40(6): 2829-2835
- 9) **Non-Hodgkin's lymphoma during pregnancy: Treatment - Health Professional Information:**
- 10) **National Cancer Institute** via the Internet web site at <http://cancer.gov> or call 1-800-4-CANCER
- 11) C.C. Lees, M. Tsigotis, J.V.L. Carr and M.A. Richards' **T cell non-Hodgkin's lymphoma presenting in the first trimester of pregnancy** Postgrad Med J 1994; 70: 371-372.
- 12) Masuhiro Kazuo. **Successful chemotherapy during pregnancy complicated with non- Hodgkin's lymphoma.** Advances In Obstetrics And Gynecology. 2001; 53(4): 323-328.
- 13) J.M. Rodriguez and M. Haggag. **VACOP-B chemotherapy for high grade non-Hodgkin's lymphoma in pregnancy;** Clinical oncology 1995; 7(5): 319-320.
- 14) Michael Herold, Sabine Schnohr, Hans Bittrich. **Efficacy and Safety of a Combined Rituximab Chemotherapy during Pregnancy** Journal of Clinical Oncology, 2001; 19(14): 34-39.
- 15) **Pregnancies after high-dose chemotherapy and autologous stem cell transplantation ASCT in aggressive lymphomas.** Blood, 2002; 100(2): 736-736.
- 16) Thomas P. Miller. Steve Dahlberg. **Chemotherapy alone compared with Chemotherapy plus Radiotherapy for localized Intermediate and High grade Non-Hodgkin's Lymphoma.** The new England Journal of Medicine 1998; 339(2): 21- 26.