



## Lymphoplasmacytic lymphoma or Plasmacytoma of the Ovary? A case report and a literature Review

Tiziana Tomaselli <sup>1</sup>, Drusilla Rollo <sup>1</sup>, Francesco Tarsitano <sup>1</sup>, Rosangela Trezzi <sup>2</sup>, Claudio Crescini <sup>1</sup>

<sup>1</sup> Department of Gynecology and Obstetrics, ASST Bergamo Ovest, Treviglio, Italy.

<sup>2</sup> Department of Pathology, ASST Papa Giovanni XXIII, Bergamo, Italy.

### ABSTRACT

Extramullary plasmacytoma (EMP) are rare neoplasms, most commonly occurring in the upper respiratory tract and rarely arise in the ovary. A 46-year-old woman presented with a history of abdominal mass associated with acute episodes of pain. A mobile abdomino-pelvic mass measuring 13.6 x 8.8 cm arising from the right adnexa. The patient subsequently underwent an exploratory laparotomy. We report the nine such case ever identified in the literature. These tumors are usually large at the time of presentation, more likely involving the left ovary and usually without evidence of disseminated disease. Adjuvant treatment for ovarian plasmacytomas is not clearly established; however, if complete surgical resection is achieved and no evidence of multiple myeloma is found, observation should be strongly considered.

**Keywords:** extramedullary plasmacytoma, neoplasms, lymphoplasmacytic.

### INTRODUCTION

Extramullary plasmacytoma (EMP) are rare neoplasms, most commonly occurring in the upper respiratory tract and rarely arise in the ovary. Review of the literature reveals nine previously reported cases of ovarian plasmacytomas.

Lymphoplasmacytic lymphoma is an indolent B cell lymphoma commonly with bone marrow and lymphonode involvement. Extranodal involvement is rare, and in the ovary extremely rare<sup>(1)</sup>. Unfortunately, there has been no consistent immunologic evaluation of such specimens nor has systematic workup or follow-up been discussed.

### SOMMARIO

Il plasmocitoma extramidollare (EMP) è una rara neoplasia, insorge più comunemente a livello delle vie respiratorie alte e più raramente a livello ovarico. Una donna di 46 anni si è presentata alla nostra attenzione con una storia di massa addominale associata a episodi acuti di dolore. Una massa addomino-pelvica delle misure 13,6 x 8,8 cm a carico dell'annessò di destra. La paziente successivamente è stata sottoposta a laparotomia esplorativa. Riportiamo di seguito il nono caso di questo tipo di tumore mai descritto in letteratura. Questi tumori sono solitamente di grandi dimensioni al momento della diagnosi, più spesso a carico dell'ovaio di sinistra e di solito senza evidenza di malattia disseminata. Non è chiaro il ruolo di un trattamento adiuvante per i plasmocitomi ovarici. Tuttavia, se si raggiunge la resezione chirurgica completa e non vi è nessuna evidenza di mieloma multiplo, dovrebbe essere fortemente considerata un condotta di osservazione.

### CASE REPORT

A 46-year-old woman presented with a history of abdominal mass associated with acute episodes of pain.

On vaginal and rectal examination, the uterus and cervix felt normal. A mobile abdomino-pelvic mass measuring 13.6 x 8.8 cm arising from the right adnexa. There was tenderness during examination. Bilateral parametria were supple and rectal mucosa was free. Except for a haemoglobin level of 10.3 g/dl, the remainder of the haemogram, serum biochemistry, chest X-ray, serum anti-HbsAg and HCV levels were normal. Serum cancer antigen Ca125: 25.2 U/ml; Ca15.3: 35.8 U/ml; Ca19.9: 6.1 U/ml, CEA: 0.4 ng/ml. An ultrasound revealed the presence of heterogeneous mass measuring 13,6x8,8 cm with

Correspondence to: [fratarsitano@hotmail.it](mailto:fratarsitano@hotmail.it)

Copyright 2015, Partner-Graf srl, Prato

DOI: 10.14660/2385-0868-36

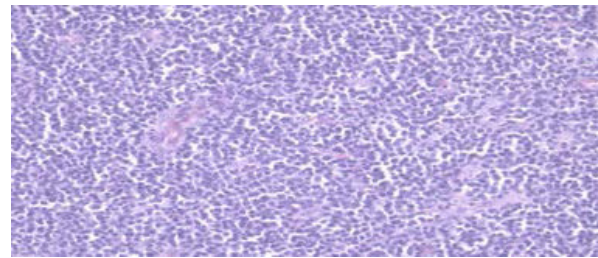
multiple septa. A CT scan of the abdomen showed a large pelvic mass measuring 12x12x14 cm arising from the right adnexa with a solid area measuring 8 cm. No ascites and others localitations.

The patient subsequently underwent an exploratory laparotomy. During surgery a complete adhesiolysis of pelvic adhesion was made. A very vascular right ovarian mass measuring 15x14x10 cm, with solid cystic areas adherent to the uterus and the sigma rectum, was seen. The cervix, appendix, omentum, and upper abdominal viscerae were normal. Left tube and ovary and right tube were removed previously. Bulky nodes were not palpable along the paraaortic and iliac regions. An intraoperative frozen section revealed the presence of poorly differentiated neoplasm carcinoma. An extrafascial hysterectomy with oophorectomy was performed. No residual tumor. Blood loss was 900 ml. She was submitted to blood transfusion and was discharged on the eighth post-operative day. Post-operative PET was negative, conversely CT scan showed millimetric peritoneal nodules. The patient was referred to the haematological oncology service and was evaluated by the multiple myeloma program to stage her plasma cell dyscrasia (complete blood count, serum protein electrophoresis, serum immunofixation, urine immunofixation and urine protein electrophoresis). She also underwent a bone marrow aspirate and biopsy with 10% plasma cells. In view of the limited anatomical disease in our case, the patient is receiving follow-up care and there wasn't any evidence of recurrence clinically in the last 16 months. Medical scans in the follow up included a CT chest, abdomen and pelvis and abdominal ultrasound. The Adjuvant treatment is not clearly established; however, if complete surgical resection is achieved and no evidence of multiple myeloma is found, observation should be strongly considered<sup>(2)</sup>.

## **PATHOLOGY**

The isthological examination revealed a diffuse ovarian infiltrate composed by clonal well differentiated plasmacells . The neoplastic population was CD138 positive and CD20 negative, with clonal expression of Lambda lighth chain (**Figure 1**).

It requested a second opinion on slides reading.



**Figure 1.**  
*Sheets of plasmablasts.*

## **DISCUSSION**

EMP is a rare primary soft tissue plasma cell tumor. These tumors are known to originate in a variety of anatomical sites, although more than 90% have been reported as developing in the head or neck area, and most of these arise in the upper respiratory passages. EMP constitute fewer than 5% of all plasma cell tumors, generally remain localized, and are more responsive to therapy<sup>(2-10)</sup>. Voegt initially reported a case of ovarian plasmacytoma in 1938; he described the tumor as the size of a fist<sup>(11)</sup>. Since that time, eight other cases, have been reported<sup>(12-16)</sup> (**Table 1**). Review of the reported cases reveals inconsistent evaluations; review of the literature reveals that in the early years the principal form of treatment of EMP was surgery for accessible lesions. However, the current treatment of choice is radiotherapy for localized disease<sup>(2,5,8,10,17,18)</sup>. The median survival of patients with EMP is reported to vary from 4-10 years<sup>(2,17,18)</sup>. Only one experience exists regarding adjuvant postsurgical therapy for patient with extramedullary plasmacytoma of the ovary. Shakuntala et al. reported a patient start three cycles of single agent carboplatin for rapidly refilling ascites and pleural effusion<sup>(19)</sup>. In summary, extramedullary plasmacytomas is an exceedingly uncommon tumor, especially with solitary involvement of the ovary. We report the nine such case ever identified in the literature. These tumors are usually large at the time of presentation, more likely involving the left ovary and usually without evidence of disseminated disease. Adjuvant treatment for ovarian plasmacytomas is not clearly established; however, if complete surgical resection is achieved and no evidence of multiple myeloma is found, observation should be strongly considered<sup>(2)</sup>.

A clonal plasma cell proliferation can be the expression of a plasmacytoma or a lymphoplasmacytic lymphoma with an extreme plasma cells differentiation.

This case propose the differential diagnoses between this two entities. Although the CD20 negativity the patient has also a nodal involvement so the clinical data suggested the final diagnosis of B lymphoma.

Primary lymphoma of ovary is rare and can be of Burkitt's, T or B cell types.

Lymphomas secondarily involving ovary are seen in up to 25% of advanced cases. Majority of cases will have concomitant lymphadenopathy. Grossly, the ovarian surface is smooth and parenchymal involvement can be partial or complete. Bi-laterality is encountered in 60% of cases. Burkitt, diffuse large B cell, follicular

lymphoma, plasmacytoma, Hodgkin lymphoma and many others were reported<sup>(20)</sup> (Table 1).

Written informed consent was obtained from the patient for publication of this Case Report and any accompanying images.

The author(s) declare that they have no competing interests. All authors deny any financial and personal relationships with other people or organizations that could inappropriately influence their work and affirm that the manuscript has not been published previously and is not being considered concurrently by another publication.

**Table 1.**

*Clinical characteristics, pathologic variables, Ca125 and outcome for the nine reported cases of ovarian plasmacytoma.*

Author	Age/ symptoms	Ovarian size/side	Ig	Ca125 and LDH	Postsur. CT	FUP	FUP status
Voegt 1938	30/ no symptoms	"fist"	NA	NA	NA	NA	NA
Bambirra 1984	44/abd. pain	Right: 14.3x5.3x4cm Left: 12.3x9x36cm	IgG	NA	NA	3 months	DOD
Hautzer 1984	56/ abd. mass	Left: 24x31x14.3cm	IgG	NA	NA	NA	NA
Talerman 1987	35/abd. mass	Unilateral: 15.3x12.3x9cm	NA	NA	NA	9 months	NA
Cook 1988	63/abd. mass	Left: 12.3x10x3.7cm	IgA	NA	NA	24 months	NA
Andze 1993	12/pelv. mass	Left: 12.3x8x3.8cm	Negative	NA	NA	11 months	NA
Emery JD 1999	54/abd. swell	Left: 15.3x13x3.8cm	IgG	NA	NA	24+months	NED
Zhong YP 2012	54/abd.pain	Right: 12x12x10cm	MM IgA-κ typeIII stage A	NA	Proposed- bortezomib and dexamethasone, etoposide, cyclophosphamide and cisplatin	NA	NA
Shakuntala 2012	35/abd.mass	Right: 14x13.5x6cm	Not done	178 and 899	Weekly carboplatin AUC2	Postsurgical Ca125: 17.7U/ml 14 months	NED

## REFERENCES

- 1) A. Albawardi, A. Casella, S.S. Almarzooq: **Lymphoplasmacytic lymphoma-Waldenström macroglobulinemia: an unusual presentation in ovaries, fallopian tubes and uterine cervix.** Int J Clin Exp Med. 2013; 6(5): 346-350.
- 2) Emery JD, Kennedy AW, et al: **Plasmacytoma of the ovary: a case report and literature review.** Gynecol Oncol 73: 151-154, 1999
- 3) Dolin S, Dewar JP: **Extramedullary plasmacytoma.** Am J Pathol 32:83-103, 1956
- 4) Batsakis JG, Fried GT, Goldman RT, Karlsberg RC: **Upper respiratory tract plasmacytoma.** Arch Otolaryngol 79:613-618,1964
- 5) Poole AG, Marchetta FC: **Extramedullary plasmacytoma of the head and neck.** Cancer 22:14-21,1968
- 6) Castro EB, Lewis JS, Strong EW: **Plasmacytoma of paranasal sinuses and nasal cavity.** Arch Otolaryngol 97:326-329,1973
- 7) Webb HE, Harrison EG, Masson JK, Remine WH: **Solitary extramedullary myeloma (plasmacytoma) of the upper part of the respiratory tract and airway.** Cancer 15:1142-1155, 1962
- 8) Wiltshaw E: **The natural history of extramedullary plasmacytoma and its relation to solitary myeloma of bone and myelomatosis.** Medicine 55:217-237,1976
- 9) Woodruff RK, Whittle JM, Malpas JS: **Solitary plasmacytoma. I. Extramedullary soft tissue plasmacytoma of bone.** Cancer 43: 2344-22347, 1979
- 10) Knowling MA, Harwood AR, Bergsagel DE: **Comparison of extramedullary plasmacytomas with solitary and multiple plasma cell tumors of bone.** J Clin Oncol 1:255-262,1983
- 11) Voegt H. Extramedullary plasmacytoma: **Virchows Arch (Pathol Anat)** 302:497-508,1938
- 12) Bambirra EA, Miranda D, Magalhaes GMC: **Plasma cell myeloma simulating Krukenberg's tumor.** South Med J 75:511-512,1982
- 13) Hautzer NW: **Primary plasmacytoma of ovary.** Gynecol Oncol 18:115-118, 1984
- 14) Talerman A: **Nonspecific tumors of the ovary, including mesenchymal tumors and malignant lymphoma.** In Kurman RJ (ed): Blaustein's pathology of the female genital tract, 3rd ed, New York, Springer-Verlag, 1987, p738
- 15) Cook HT, Boylston AW: **Plasmacytoma of the ovary.** Gynecol Oncol 29: 378-381, 1988
- 16) Andze G, Pagbe JJ, Tchokoteu PF, et al: **Le plasmacytome solitaire extraosseux ovarien.** J Chir 130:137-140, 1993
- 17) Mayr NA, Wen BC, Hussey DH, et al: **The role of radiation therapy in the treatment of solitary plasmacytomas.** Radiother Oncol 17: 293-303, 1990
- 18) Wasserman TH: **Diagnosis and management of plasmacytomas.** Oncology 1(2): 37-41,1987
- 19) Shakuntala PN, Praveen SR, Shankaranand B, et al: **A rare case of plasmacytoma of the ovary: a case report and literature review.** Ecancer 2013, 7:288
- 20) Shacham-Abulafia A, Nagar R et al. **Lymphoma of the ovary: case report and review of the literature.** Acta Heam 2012;129:169-174